

Goldsmiths Research Online

*Goldsmiths Research Online (GRO)
is the institutional research repository for
Goldsmiths, University of London*

Citation

Chamberlain, Rebecca; McManus, I. C.; Brunswick, Nicola; Rankin, Qona; Riley, Howard and Kanai, Ryota. 2014. Drawing on the right side of the brain: a voxel-based morphometry analysis of observational drawing. *NeuroImage*, 96(1), pp. 167-173. ISSN 1053-8119 [Article]

Persistent URL

<http://research.gold.ac.uk/20007/>

Versions

The version presented here may differ from the published, performed or presented work. Please go to the persistent GRO record above for more information.

If you believe that any material held in the repository infringes copyright law, please contact the Repository Team at Goldsmiths, University of London via the following email address: gro@gold.ac.uk.

The item will be removed from the repository while any claim is being investigated. For more information, please contact the GRO team: gro@gold.ac.uk

**DRAWING ON THE RIGHT SIDE OF THE BRAIN: A VOXEL-BASED
MORPHOMETRY ANALYSIS OF OBSERVATIONAL DRAWING**

Rebecca Chamberlain^{1a}

I. Chris McManus²

Nicola Brunswick³

Qona Rankin⁴

Howard Riley⁵

Ryota Kanai⁶

¹Laboratory of Experimental Psychology, University of Leuven, Belgium. Email: Rebecca.Chamberlain@ppw.kuleuven.be; Postal Address: Tiensestraat 102, 3000 Leuven, Belgium. ²Research Department of Clinical, Educational and Health Psychology, Division of Psychology and Language Sciences, University College London, UK; ³Department of Psychology, School of Health and Social Sciences, Middlesex University, London, UK; ⁴Royal College of Art, London, UK; ⁵ Faculty of Art and Design, Swansea Metropolitan University of Wales Trinity Saint David; ⁶ School of Psychology, Sackler Centre for Consciousness Science, University of Sussex, Falmer, UK.

^a Corresponding author.

Abstract

Structural brain differences in relation to expertise have been demonstrated in a number of domains including visual perception, spatial navigation, complex motor skills and musical ability. However no studies have assessed the structural differences associated with representational skills in visual art. As training artists are inclined to be a heterogeneous group in terms of their subject matter and chosen media, it was of interest to investigate whether there would be any consistent changes in neural structure in response to increasing representational drawing skill. In the current study a cohort of 44 graduate and post-graduate art students and non-art students completed drawing tasks. Scores on these tasks were then correlated with the regional grey and white matter volume in cortical and subcortical structures. An increase in grey matter density in the left anterior cerebellum and the right medial frontal gyrus was observed in relation to observational drawing ability, whereas artistic training (art students vs. non-art students) was correlated with increased grey matter density in the right precuneus. This suggests that observational drawing ability relates to changes in structures pertaining to fine motor control and procedural memory, and that artistic training in addition is associated with enhancement of structures pertaining to visual imagery. The findings corroborate the findings of small-scale fMRI studies and provide insights into the properties of the developing artistic brain.

DRAWING ON THE RIGHT SIDE OF THE BRAIN

Highlights:

1. We measure structural differences in GM and WM in art students and non-art students
2. We correlate GM and WM volume and performance on drawing tasks
3. Drawing skill linked to increased GM in the cerebellum and medial frontal gyrus
4. Drawing relates to changes in fine motor structures in art and non-art students

Keywords: Art, Drawing, Cerebellum, Expertise, Voxel-based Morphometry

1. Introduction

The production of representational art is one of the most complex and intangible human behaviours; a form of expression which is almost as old as the modern human and far predates evidence of written communication. The earliest known rock art found in Africa arguably dates back to about 75,000 years ago, with cave art found in the caves of Chauvet, Lascaux and Altamira in France and Spain dating back roughly 40,000 years (Blum, 2011).

As a result of the infancy of research into representational art making, a sparse amount is known about how the brain accomplishes such a task, contrasting with other complex creative tasks such as musical production, whose neural bases have received much attention in the past decade (Bangert et al., 2006; Gaser & Schlaug, 2003; Koeneke, Lutz, Wustenberg, & Jäncke, 2004; Schlaug, Jäncke, Huang, & Steinmetz, 1995; Schlaug, 2001; Zatorre, 2003). Representational *drawing* in particular lends itself to empirical study in this domain as input can be compared directly with output to provide a quantitative measure of ability.

Neurological and neuroimaging research concerning representational drawing previously focused upon the distinct roles of the two cerebral hemispheres, with different drawing pathologies manifesting with left and right-brain damaged patients (Chatterjee, 2004). This was compounded by the popularity of 'Drawing on the Right Side of the Brain' (Edwards, 1989) which conjectured that switching into 'R-Mode' (engagement with the right brain and its putative holistic perceptual processes) helps novices to master representational drawing skills. Although Edwards (1989) was influential, the use of right and left in the text was to a large extent metaphorical rather than neuropsychological.

DRAWING ON THE RIGHT SIDE OF THE BRAIN

Neuropsychological research into constructional apraxia implicates brain regions that underpin the integration of multimodal perceptual data, largely involving the parietal cortices (Gainotti, 1985). Neuroimaging data have corroborated the findings of neuropsychological studies as parietal regions have been found to be functionally more active when drawing faces compared to drawing geometrical figures (a motor control; Solso, 2001), when drawing stimuli from memory compared to visually encoding them (Miall et al, 2009) and when drawing stimuli compared to naming them (Makuuchi et al, 2003). In addition, activation in motor regions and the cerebellum was found when drawing was compared with encoding and naming tasks (Miall et al, 2009). As well as transient functional changes in neural activity in relation to drawing, evidence has been found for structural and functional changes over time as a result of artistic training. Schlegel et al (2012) found that novices who had undergone an intensive drawing and painting course showed increased activation in the right cerebellum whilst performing gestural drawing revealed through functional classification, and structural changes in right inferior frontal regions revealed by fractional anisotropy (FA). This study suggests that structural changes occur in the brain as a result of artistic training, in much the same way as been found previously in various populations of experts from musicians (Gaser & Schlaug, 2003) to taxi drivers (Maguire et al., 2000; Woollett & Maguire, 2011).

Whilst there appear to be short-term functional changes in brain regions associated with motor ability in response to drawing practice (Schlegel et al., 2012) it is unclear whether the same or functionally higher-level brain regions are implicated in longer-term drawing skill development that takes place over years rather than months. Furthermore, drawing tasks used in previous studies have been conducted inside the MRI scanner, and may lack ecological validity

DRAWING ON THE RIGHT SIDE OF THE BRAIN

(Ferber et al., 2007). Therefore, a more extensive voxel based morphometry study of drawing ability in art and non-art graduate and post-graduate students was undertaken in the current study. It was hypothesised that individuals with greater representational expertise might show increased cortical gray and white matter bilaterally in parietal regions, more specifically the superior parietal lobule and intraparietal sulcus on the basis of prior functional evidence (Makuuchi et al., 2003). Functional studies also point toward involvement of frontal regions, particularly the supplementary motor areas (Miall et al., 2009; Makuuchi et al., 2003; Ferber et al., 2007) and the cerebellum (Makuuchi et al., 2003; Schlegel et al., 2012) and therefore these regions were also hypothesised to be correlated with drawing ability. The effect of artistic training on brain structures was also of interest in addition to the more specific skill of representational drawing. Therefore a structural group comparison was made between an art-student group and a non-art student group, taking individual differences in representational drawing ability into account.

2. Materials and Methods

2.1 Participants

2.1.1 Art Students.

Participants ($n=21$; 14 female; mean age =26.0 ($SD = 5.9$) years) were recruited from respondents of a larger questionnaire based study ($N=88$) conducted in September 2011. That sample included undergraduate ($n=14$) and post-graduate ($n=74$) students attending art and design courses in London at Camberwell College of Art (CAM) and The Royal College of Art (RCA) respectively. There were 6 students from CAM and 15 students from RCA in the neuroimaging sample. Each art college has entrance criteria based on the assessment of artistic talent, primarily in the form of a portfolio of work. CAM requires completion of a foundation diploma in art and design (a one-year diagnostic course) to a high standard and a portfolio of work, and RCA requires a high quality portfolio of work indicating competence in a specific discipline within the general field of art and design practice, for example painting, product design or photography. The majority of students had completed a BA in an arts subject and many were practising artists seeking to consolidate or broaden their artistic practice. Four of the art student participants were left-handed, the remaining 17 participants were right-handed.

2.1.2 Controls.

Control participants ($n=23$; 16 female; mean age =25.8 ($SD = 7.1$) years) were recruited from the undergraduate and post-graduate student population at University College London (UCL).

Participants studied a range of non-visual-arts degrees and did not differ significantly in age, $t(42) = .06$, $p = .95$, to the art student sample. Within the control group 17 participants had no

DRAWING ON THE RIGHT SIDE OF THE BRAIN

artistic experience, 5 reported pursuing artistic activities in their spare time very occasionally, and one participant reported often pursuing artistic activities in their spare time. One control participant was left-handed, the remaining 22 participants were right-handed.

2.2 Ethics

The study was approved by the Ethical Committee of the Clinical, Educational and Health Department of Psychology of UCL.

2.3 Procedure

Participants were tested individually on all tasks within one testing session lasting between 1-1.5 hours at the psychology department at UCL. Tasks were administered in the order presented in the experimental procedure.

2.3.1 Questionnaire Measures.

Participants completed a questionnaire consisting of four A4 sides, presented as a single folded sheet of A3 paper. The questionnaire included questions on:

Drawing and Painting Experience (Art Students Only). Art students were asked how much time they spent drawing and how much time they spent painting both currently and over each of the previous two years using an 11-point scale ranging from 'most days for 4+ hours' to 'never'.

Artistic Experience (Controls Only). Control students were asked if they undertook any artistic activities including painting, drawing or photography and responded on a 4 point scale from 'none' to 'as part of my university course'. This measure was taken to assess the control

participants' involvement in artistic related activities to ensure differences in the degree of artistic training across the two participant groups.

2.3.2 Shortened Form of Ravens Advanced Progressive Matrices.

To account for potential IQ-based confounds between the art students and non-art students, a shortened form of Ravens Advanced Progressive Matrices (RAPM) was administered (Arthur & Day, 1994). This form has been validated and normalised (Arthur, Tubre, Paul, & Sanchez-Ku, 1999) and as such represents a valid predictor of non-verbal IQ (NVIQ). Participants were given one practice item from Set I of the RAPM. They were then given 12 items from Set II of the longer 36 item RAPM to complete in 15 minutes. Stimuli were presented on paper and participants gave their responses verbally. All participants completed the task in the allotted time.

2.3.3 Observational Drawing Tasks.

Drawing tasks were completed on A4 (297 × 210 mm) heavy-weight art paper (130 g.m⁻²). Participants were provided with B pencils, erasers and sharpeners. Stimuli were presented via timed slides within a Microsoft Office PowerPoint presentation on a 13 inch liquid crystal computer screen with a 60Hz refresh rate (see Figure 1 for photographs of stimuli). Participants were instructed to make an accurate drawing of a photograph of a hand holding a pencil, and of a block construction (5 min per image).

2.4 Drawing Rating Procedure

Black and white digitised images of the drawings and the original image were printed out onto sketching quality paper, reduced from A4 to A5 size. The images were then rated by a

DRAWING ON THE RIGHT SIDE OF THE BRAIN

convenience sample of ten non-expert judges consisting of post-graduate and undergraduate students at UCL. Each judge was required to rate the drawings from best to worst by sorting them into seven categories. Judges were informed that quality of drawing was to be determined solely on the basis of accuracy, and not on aesthetic appeal. Exemplars of the quality of drawing accuracy in each category from a previous study were given to the judges in order to aid the rating process. The judges were not restricted in terms of how many drawings they put into each category.

When the judges were satisfied with their distribution of drawings, each drawing was assigned the number of the category into which it was placed in (8 – best, 2 – worst). If the judge felt that a particular drawing was better than the best exemplar, that drawing received a score of 9, and if a drawing was rated as worse than the worst exemplar, it received a score of 1, although these extremes of the scale were used rarely.

Participants' scores for the hand and block drawings were averaged across the ten non-expert raters. Inter-rater reliability was high with a Cronbach's alpha of .92 for hand drawing ratings and .93 for block drawing ratings. Hand drawing ratings were highly positively correlated with block drawing ratings, $r(44) = .83$, $p < .001$, and therefore a composite drawing rating was produced by averaging drawing ratings for the hand and blocks for each participant.

Variables of Interest

The two variables of interest were derived from performance on the observational drawing task and differences between the two participant groups:

DRAWING ON THE RIGHT SIDE OF THE BRAIN

Drawing ability. The ability to construct the *secondary geometry* relationships (ie the 2-D drawing) so as to match the *primary geometry* relationships (ie the relationships between the actual edges and corners of a 3-D scene as seen from a fixed viewpoint, such as represented in a photograph).

Artistic training. Whether participants belonged to the art-student or non-art student groups outlined in the participants section.

2.5 Image Acquisition and Analyses

MR images were acquired on a 1.5 Tesla Siemens Avanto MRI scanner (Siemens Medical, Erlangen, Germany) with a 32-channel head coil. High-resolution whole-brain MR images were obtained using a T1-weighted three-dimensional magnetization-prepared rapid acquisition gradient-echo sequence (MPRAGE; repetition time=2.73s; echo time=3.57 ms; voxel size=1.0×1.0×1.0 mm).

2.6 Voxel-Based Morphometry Protocol and Data Pre-processing

2.6.1 White and Grey Matter Analysis.

The MR images were first segmented for grey matter (GM) and white matter (WM) using the segmentation tools in SPM8 (<http://www.fil.ion.ucl.ac.uk/spm>). Subsequently, a Diffeomorphic Anatomical Registration Through Exponentiated Lie Algebra (DARTEL) (34) in SPM8 was performed for inter-subject registration of the GM images (Ashburner, 2007; Ashburner and Friston, 2000). In this co-registration pre-processing, local GM volumes were conserved by modulating the image intensity of each voxel by the Jacobian determinants of the deformation fields computed by DARTEL. The registered images were smoothed with a

DRAWING ON THE RIGHT SIDE OF THE BRAIN

Gaussian kernel (FWHM = 8 mm) and were then transformed to MNI stereotactic space using affine and nonlinear spatial normalisation implemented in SPM8 for multiple regression and factorial ANOVA.

The pre-processed images were entered into a series of multiple regression models in SPM5. A statistical threshold of $p < 0.05$ corrected for the whole-brain volume at a cluster level using the 'Non-Stationary Cluster Extent Correction for SPM5 toolbox (<http://fmri.wfubmc.edu/cms/NS-General> (Hayasaka, Phan, Liberzon, Worsley, & Nichols, 2004)) was used as an indicator of regions of significant correlation between the behavioural variables and grey matter density. We aimed to identify cortical regions that showed correlations with:

- a. Drawing ability
- b. Artistic training

The first regression included drawing and artistic training (art students vs. non-art students) as covariates of interest, as artistic training and drawing ability were likely to be conflated in this study, and it was of interest to assess the independent relationship of each factor to its neural substrate. Age, gender and total grey matter volume (following ANCOVA normalisation) were included as covariates of no interest in the model. In the second regression model artistic training was included as the covariate of interest and the same covariates of no interest were added to the model.

3. Results

3.1 Behavioural Data

A range of the drawings produced is shown in Figure 1. A series of paired samples t-tests were conducted to identify significant differences in performance between the two groups. There were significant differences in performance on the drawing tasks. Artists' drawing ratings were on average 1.42 points higher than non-artists' ratings, $t(42) = 3.51$, $p < .01$, which supports a regression model that includes both artistic and drawing ability as covariates, as differences in grey matter could be attributed to either drawing or artistic ability given that the two participant groups differ in both respects. There were no significant differences in NVIQ between the artist and control groups, $t(42) = .84$, $p = .41$. Average points on a logarithmic scale for time spent drawing in the artist sample was 25.62 (SD=11.53), which corresponds to two hours per week spent drawing over the previous two years.

DRAWING ON THE RIGHT SIDE OF THE BRAIN

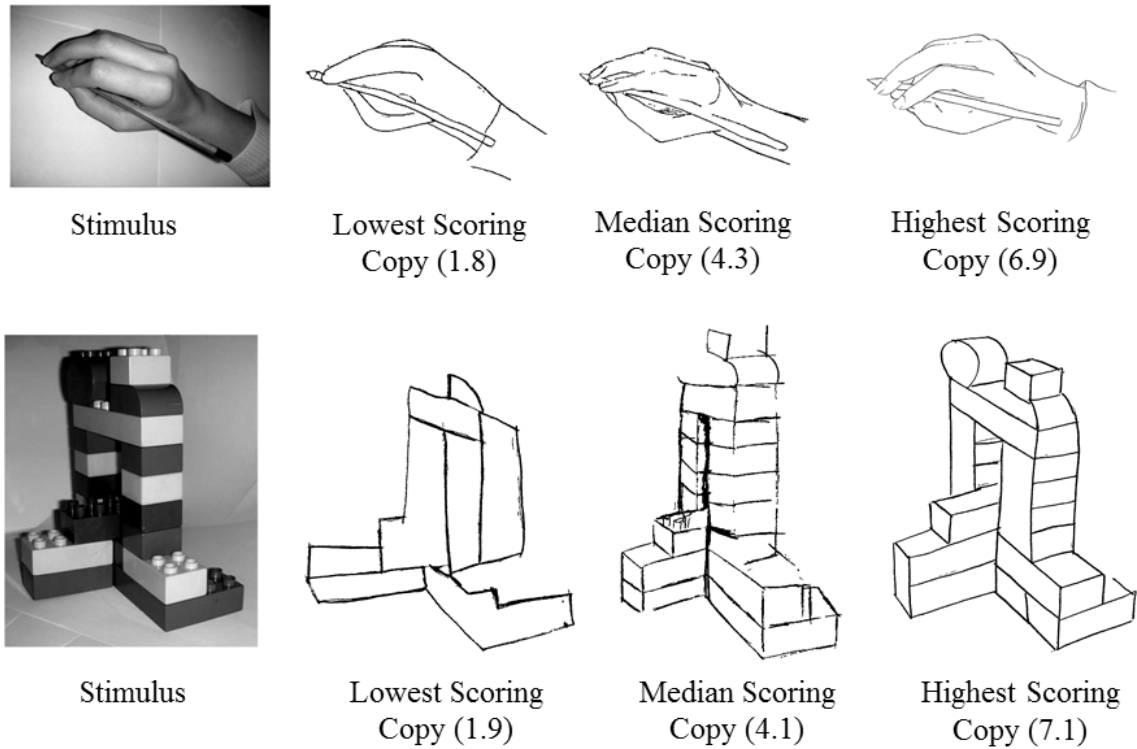


Figure 1. Hand and block drawing task stimuli and highest, lowest and median scoring drawings on each task.

3.2 Whole Brain Analysis Grey Matter

Regression analyses were conducted on GM segregated scans across the whole brain. Artistic training (art students vs. non-art students) and drawing ability were explored in a multiple regression.

3.2.1 Drawing and Artistic Training

VBM analysis was used to explore the correlations between local grey matter density and drawing and artistic training. At a rigorous statistical threshold of $p < .05$ corrected for multiple comparisons across the whole brain volume significant correlations between grey matter density

DRAWING ON THE RIGHT SIDE OF THE BRAIN

and drawing accuracy were found in the left anterior cerebellar cortex (Table 1; $T(44)=4.74$, $P=.036$ FWE-corrected for the whole brain; peak MNI coordinate $x=-44$, $y=-51$, $z=-28$; Figure 2). Regions showing significant correlations between neural structure and drawing and artistic training (art students vs. non-art students) at a more liberal statistic threshold of $P_{\text{uncorrected}} < .001$ are also reported in Table 1. Although these results need to be interpreted with caution, they are included in our report to facilitate the interpretation of results and meta-analysis on this topic in future work. No significant correlations were found between regions of decreased cortical or subcortical grey matter and drawing ability or artistic training.

Table 1. Brain regions in which grey matter density significantly positively correlated with drawing and artistic training ($p < .05$ uncorrected).

	<i>Anatomy (Brodmann Area)</i>	<i>MNI coordinates</i>			<i>Cluster Size (mm³)</i>	<i>Z</i>	<i>P_{uncorr}</i>	<i>P_{corr}</i>
		<i>X</i>	<i>Y</i>	<i>Z</i>				
	Left Anterior Cerebellum	-44	-51	-28	935	3.99	.00	.00
Drawing	Right Medial Frontal Gyrus (BA 6)	8	-25	56	288	4.17	.02	.18
Artist	Right Precuneus (BA 31)	9	-55	33	187	3.70	.05	.42

Notes: Artist= Artist/Non-artist, Drawing=Drawing rating.

DRAWING ON THE RIGHT SIDE OF THE BRAIN

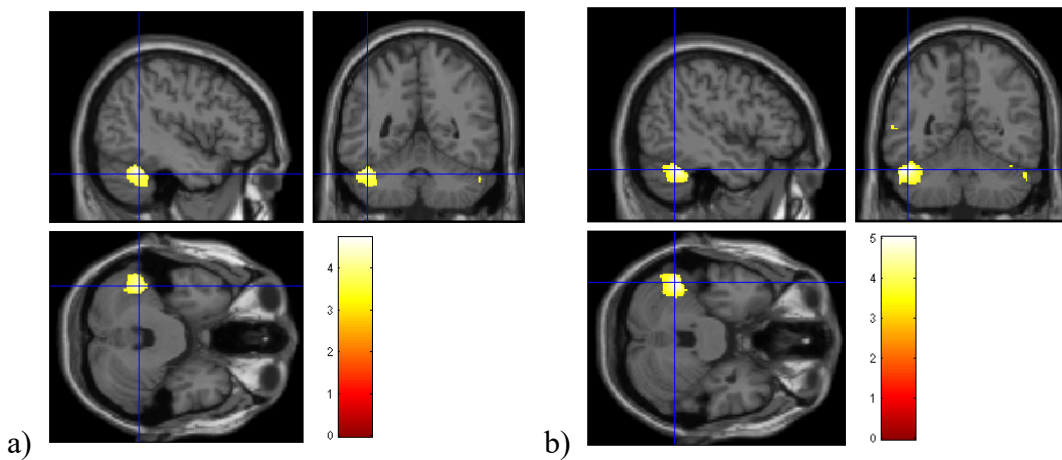


Figure 2. a) Grey matter volume significantly positively correlated with drawing accuracy at cluster level with whole brain analysis correction for multiple comparisons ($p < .05$) b) Grey matter volume significantly positively correlated with drawing accuracy at cluster level with whole brain analysis correction for multiple comparisons for right handed participants ($n=39$; $p < .05$).

3.2.2 Separate analyses in left and right handers to account for ipsilateral cerebellar findings

Due to the fact that correlations between drawing ability and grey matter volume were found in the left cerebellar hemisphere (corresponding to control of the ipsilateral hand; Manni & Petrosini, 2004) the GM analysis was repeated just for right handed participants to ascertain whether this finding was dependent on handedness. This analysis was conducted to rule out the possibility that correlations between grey matter density and drawing were driven by the larger proportion of left-handed participants in the artist group who were also statistically better at drawing than the non-artist group. The two groups could not be directly compared as the sample size for the left-handed group was too small, however this analysis permits the identification of the pattern of results as being qualitatively similar in both left and right-handers. If the pattern of data is the same in right handers, it can be concluded that the correlation between drawing ability

DRAWING ON THE RIGHT SIDE OF THE BRAIN

and GM in left cerebellar regions is not due to the larger proportion of left-handers in the art student subsample.

Table 2. Brain regions in which grey matter density significantly positively correlated with drawing and artistic training in right handers ($p < .05$ uncorrected).

	<i>Anatomy</i> (<i>Brodman Area</i>)	<i>MNI</i> <i>coordinates</i>			<i>Cluster</i> <i>Size</i>	<i>Z</i>	<i>P_{uncorr}</i>	<i>P_{corr}</i>
		<i>X</i>	<i>Y</i>	<i>Z</i>				
Drawing	Left Anterior Cerebellum	-47	-52	-28	1482	4.32	.00	.01
	Right Medial Frontal Gyrus (BA 6)	8	-24	56	397	3.77	.04	.15

Notes: Artist= Artist/Non-artist, Drawing=Drawing rating.

In this instance it can be seen that correlations between drawing and grey matter volume remain in the same regions for the right handed participants as for the participant group as a whole (Table 2). However, differences between art students and controls are no longer present in this analysis. At a more rigorous statistical threshold of $p < .05$ corrected for multiple comparisons across the whole brain volume significant correlations between grey matter density and drawing ratings was found in the left anterior cerebellar cortex as in the previous analysis ($T(39)=5.03$, $P = .010$ FWE-corrected for the whole brain; peak MNI coordinate $x=-47$, $y=-52$, $z=-28$).

3.2.3 Between and within-group differences explanations for increased GM in the cerebellum

DRAWING ON THE RIGHT SIDE OF THE BRAIN

It was necessary to establish whether the correlation between GM density and drawing ability was a result of between- or within-group differences. Thus the GM density in peak voxels in the cerebellum was extracted for each participant and then correlations between GM density for peak left cerebellar voxels and drawing score were assessed in each group separately. In both the artist, $r(21) = .38$, $p = .07$, and the non-artist, $r(23) = .63$, $p < .01$, subgroups, there was a positive correlation between GM density in the cerebellum and drawing scores. There was no significant difference between these two correlations. The artist group had slightly higher GM density in the left cerebellar region of interest, but this difference was not significant, $t(42) = 1.84$, $p = .07$.

3.3 Whole Brain Analysis White Matter Density

The same regression analyses that were conducted on GM volumes across the whole brain were conducted for the WM segregated scans. Artistic training and drawing ability were explored in a multiple regression.

3.3.1 Drawing and Artistic Training.

The results of the WM density analysis to some extent support the findings from the GM analysis. In this instance there was found to be increased WM density in the left cerebellar lobe, but in a region more posterior to that found in the GM analysis (Table 3). This region was not found to be significant when a corrected $p < .05$ threshold due to multiple comparisons was taken into account. There were no regions of increased WM density that significantly correlated with artistic training. There was found to be a region of the left precentral gyrus in which WM density correlated negatively with artistic training. However, this contrast was not significant at the corrected p-value for multiple comparisons across the whole brain.

Table 3. Brain regions in which white matter density significantly correlated with drawing and artistic training ($p < .05$ uncorrected).

	<i>Anatomy</i> (<i>Brodman Area</i>)	<i>MNI</i> <i>coordinates</i>			<i>Cluster</i> <i>Size</i>	<i>Z</i>	<i>P_{uncorr}</i>	<i>P_{corr}</i>
		<i>X</i>	<i>Y</i>	<i>Z</i>				
Drawing	Left posterior cerebellar lobe	-26	-46	-45	748	3.91	.01	.18
Artist	Left precentral gyrus (BA 6)	-41	-12	63	285	-4.16	.04	.55

3.3.2 Relationship between time spent drawing and extent of grey/white matter.

Extracted GM and WM volumes from peak voxels associated with drawing ability were assessed in relation to amount of time in the previous two years spent drawing by the artistic proportion of the sample ($n=19$). There were no significant correlations between time spent drawing and GM volume in the left anterior cerebellar region or in the medial frontal lobe (both $p > .20$). There was also no significant correlation between time spent drawing and WM volume in the left posterior cerebellar region ($p = .70$).

4. Discussion

The current study sought to establish which regions of the brain were associated with drawing skill through structural analysis of grey and white matter, and dissociate these regions from brain regions associated with artistic training. It was hypothesised that regions of the brain associated with visuo-spatial and motor processing would be shown to be structurally different in proficient draughtsmen compared with novices. These hypotheses were partially supported. Increased GM and WM were related to drawing ability in the left anterior cerebellum and the right medial frontal lobe, corresponding to the supplementary motor area (SMA).

To some extent the current structural findings corroborate the findings of previous functional studies (Ferber et al., 2007; Makuuchi et al., 2003; Miall et al., 2009; Schlegel et al., 2012; Solso, 2000; Solso, 2001). The cerebellar region was found to be functionally more active in the studies of Makuuchi et al (2003), Miall et al (2009) and Schlegel et al (2012) in relation to drawing. In Makuuchi et al (2003) the left cerebellar region (peak voxel $x=-30, y=-58, z=-28$) roughly corresponds to the region found in the current study, suggesting that the cerebellum shows both functional and structural changes in relation to drawing proficiency. Whilst Schlegel et al (2012) did not find structural changes to the cerebellum after a six-month drawing and painting training course, they did find functional changes when participants performed a gestural drawing task. This suggests that functional differences in this region during task performance may give rise to structural changes over longer periods of training. It could be the case that the period of training in Schlegel et al's (2012) study was not long enough to confer lasting structural changes in the cerebellum, whereas in the current study all art students had at least three years' post-high school artistic training and an average of two hours of drawing practice

DRAWING ON THE RIGHT SIDE OF THE BRAIN

per week over the previous two years; a longer-term involvement in drawing practice.

Furthermore, as correlations between brain structure and drawing ability were found across the sample (Results 3.2.3), and amount of drawing practice was not significantly correlated with the extent of GM in the regions of interest (Results 3.3.2), it can be speculated that some of these differences in brain structure may not be a result of drawing training, but perhaps an inherent difference in fine motor control. In a case-study of an autistic savant artist, O'Connor & Hermelin (1987) concluded that 'the efficient use of domain specific motor programmes by idiot-savant artists may indicate some sparing of cerebellar and/or motor cortex structures independently of whether they are autistic or not'(p.317) suggesting that highly proficient representational drawing is associated with spared or enhanced motor structures.

Positive correlations with GM in the right medial frontal gyrus (BA 6) and drawing ability uncorrected for multiple comparisons are also in line with previous research (Makuuchi et al, 2003; Solso, 2001) but in a contrasting hemisphere to previous studies, as the authors found increased activation in the left rather than the right medial frontal gyrus on these occasions (Miall et al, 2009; Ferber et al, 2007). The region of the right medial frontal gyrus highlighted here corresponds to the SMA, the bounds of which are described in a meta-analysis and fit the coordinates of the peak voxel in this study (Mayka, Corcos, Leurgans, & Vaillancourt, 2006) and which was identified as an active region in previous research (Ferber et al., 2007; Makuuchi et al., 2003; Miall et al., 2009). In a review of the structure and function of the SMA, its role in inhibiting inappropriate behaviour toward objects was emphasised (Nachev, Kennard, & Husain, 2008). This suggests that the SMA is critical for pairing external states (visual cues) and internal states (memory) with action. This finding can provide a rational explanation for the increased

size of the SMA in the current study; it appears to be involved in integrating current visual information (the stimulus image) with hand movements necessary to replicate a specific aspect of the visual stimulus on the basis of previous experience. The SMA has also been previously associated with procedural knowledge (Ackermann, Daum, Schugens, & Grodd, 1996; Grafton et al., 1992), as has the cerebellum (Molinari et al., 1997; Torriero et al., 2007). Therefore, procedural memory could underpin the involvement of both the cerebellum and the SMA in long term drawing expertise acquisition. The role of procedural memory has been highlighted in Kozbelt and Seeley's (2007) visuo-motor model of artists' perceptual enhancements, which suggests that procedural knowledge impacts on incoming visual information, helping the artist effectively to deconstruct visual scenes.

It was expected that GM volume differences in occipital regions associated with perceptual processing would be correlated with drawing accuracy in the current study. However, in much the same manner as has been found in a previous study of visual expertise, in which a directional hypothesis focused on occipital regions as the likely neural locus of expertise (Gilaie-Dotan et al., 2012), GM and WM volume in typically 'pure' visual brain regions were not found to be correlated with drawing. It could be the case that occipital regions are too low-level and generalised to be the locus of structural changes in grey or white matter in relation to drawing ability. However, it is possible that differences in higher-level more stimulus specific regions might exist. In future research it would be advantageous to target participant groups on the basis of artistic expertise, in order to assess whether stimulus-specific structural changes occur according to specialisation. For example, portrait artists may show changes over time in the fusiform face area (FFA) of the temporal lobe. An extended version of Makuuchi et al's (2003)

DRAWING ON THE RIGHT SIDE OF THE BRAIN

model of neural correlates of drawing (Figure 3), taking into account the current data, shows that the extent to which semantic and visuo-motor regions (BA 7, 40 & 37) are involved in drawing is dependent on the kind of visual information being processed by the dorsal and ventral visual pathways. This emphasises the likelihood of stimulus-specific differences in functional and structural brain changes in relation to drawing proficiency, according to the particular visual expertise of the artist.

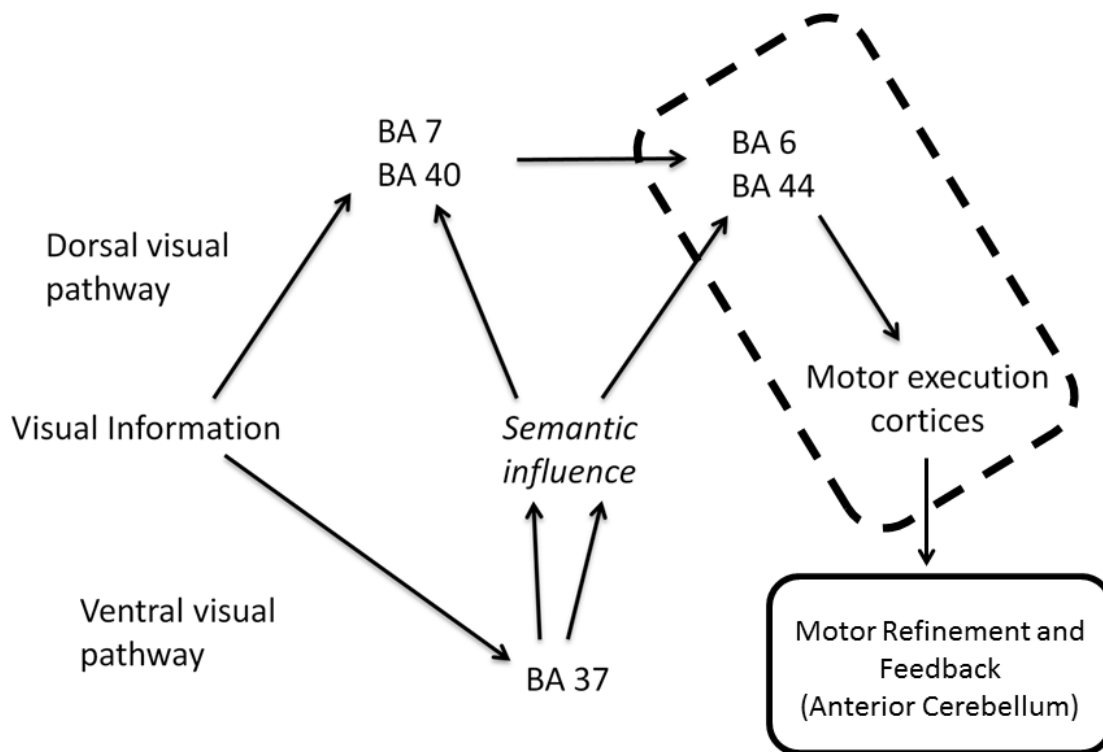


Figure 3. Adapted diagram of brain regions associated with drawing in Makuuchi et al (2003).

The region enclosed in the dotted outline were found to be associated with drawing in the current study, whilst the region enclosed in the solid outline represents novel evidence for brain regions found in the current study.

DRAWING ON THE RIGHT SIDE OF THE BRAIN

Contrasts for artists versus non-artists in the current sample revealed increased GM volume in the right precuneus (BA 31)/posterior cingulate cortex, which is located in the medial parietal lobe, in relation to artistic training, uncorrected for multiple comparisons. In a VBM study of divergent thinking as a measure of creative thinking, Takeuchi et al (2010) found increased GM volume bilaterally in the precuneus for individuals with higher divergent thinking scores. Jung et al (2010) found GM volume in a region of the right posterior cingulate correlated positively with a composite creativity index of creative achievements, design fluency and creative uses of objects. The authors suggest that the precuneus may be responsible for processes supporting creativity, particularly mental imagery, which has previously been shown to be enhanced in trained artists (Kozbelt, 2001). Mnemonic oriented visuo-spatial imagery is thought to be underpinned by premotor and postero-medial parietal connections with the posterior precuneus, whilst portions of the anterior precuneus are proposed to support intuitive mental imagery including mental rotation and deductive reasoning (Cavanna & Trimble, 2006). At this stage it is only possible to speculate on the role of the precuneus in artistic production given the number of functions it subserves including introspection (Johnson et al., 2002; Northoff et al., 2006; van der Meer, Costafreda, Aleman, & David, 2010), empathy (Banissy, Kanai, Walsh & Rees, 2012; Farrow et al., 2001; Völlm et al., 2006) and emotion (Maddock, Garrett, & Buonocore, 2003; Murphy, Nimmo-Smith, & Lawrence, 2003). In future research it will be necessary to quantify artistic ability beyond the level of academic attainment and to derive measures of creativity and imagery. This will qualify the dissociation between artists and non-artists and elaborate upon the link between the precuneus, imagery, and artistic ability.

DRAWING ON THE RIGHT SIDE OF THE BRAIN

This study has reoriented the focus of drawing ability on visuo-motor processing and procedural memory. This contrasts with an established body of behavioural evidence in this field which emphasises the role of visual perception in isolation from interaction with motor processes (Chamberlain et al, 2013; Cohen & Bennett, 1997; Drake & Winner, 2011; Kozbelt, 2001; Ostrofsky et al 2012). The results of this study suggest that there are no long-term structural changes in visual regions of the occipital cortices and in visuo-spatial higher level representations in the parietal cortices as a result of enhanced drawing ability. Instead, experience with drawing confers structural changes to the anterior cerebellum and SMA and is independent of structural differences associated with artistic training. Artistic training in a more general sense appears to be related to increased GM volume in regions of the precuneus, potentially relating to the ability to create internal visual imagery, however further measures of the various components of artistic ability would help to clarify the link between structural differences in the precuneus and artistic training. Finally, these correlations between grey and white matter and drawing proficiency appear to be independent of the degree of visual arts training and therefore may be diagnostic of proficiency in representational media.

Reference List

Ackermann, H., Daum, I., Schugens, M. M., & Grodd, W. (1996). Impaired procedural learning after damage to the left supplementary motor area (SMA). *Journal of Neurology, Neurosurgery, and Psychiatry*, *60*, 94-97.

Arthur, W. & Day, D. V. (1994). Development of a short form for the Raven Advanced Progressive Matrices test. *Educational and Psychological Measurement*, *54*, 394-403.

Arthur, W., Tubre, T., Paul, D., & Sanchez-Ku, M. (1999). College-sample psychometric and normative data on a short form of the Raven Advanced Progressive Matrices test. *Journal of Psychoeducational Assessment*, *17*, 354-361.

Ashburner J, Friston KJ. (2000). Voxel-Based Morphometry. The Methods. *NeuroImage* *11*, 805–821.

Ashburner, J (2007). A fast diffeomorphic image registration algorithm. *NeuroImage* *15*, 95–113.

Bangert, M., Peschel, T., Schlaug, G., Rotte, M., Drescher, D., Hinrichs, H. et al. (2006). Shared networks for auditory and motor processing in professional pianists: evidence from fMRI conjunction. *Neuroimage*, *30*, 917-926.

Banissy, M., Kanai, R., Walsh, V., & Rees, G. (2012) Inter-individual differences in empathy are reflected in human brain structure. *Neuroimage*, *62*, 2034-2039.

Bhattacharya, J. & Petsche, H. (2005). Drawing on mind's canvas: Differences in cortical integration patterns between artists and non-artists. *Human Brain Mapping*, *26*, 1-14.

Blum, H. P. (2011). The psychological birth of art: a psychoanalytic approach to prehistoric cave art. *Creative Dialogues: Clinical, Artistic and Literary Exchange*, 20, 196-204.

Cavanna, A. E. & Trimble, M. R. (2006). The precuneus: a review of its functional anatomy and behavioural correlates. *Brain*, 129, 564-583.

Chamberlain, R., McManus, I. C., Riley, H., Rankin, Q., & Brunswick, N. (2013) Local processing enhancements associated with superior observational drawing are due to enhanced perceptual functioning, not weak central coherence. *The Quarterly Journal of Experimental Psychology*, 66, 7, 1448-1466

Chatterjee, A. (2004). The neuropsychology of visual artistic production. *Neuropsychologia*, 42, 1568-1583.

Cohen, D. J. & Bennett, S. (1997). Why can't most people draw what they see? *Journal of Experimental Psychology: Human Perception and Performance*, 23, 609-621.

Drake, J. E. & Winner, E. (2011). Realistic drawing talent in typical adults is associated with the same kind of local processing bias found in individuals with ASD. *Journal of Autism and Developmental Disorders*, 41, 1192-1201.

Edwards, B. (1989). *Drawing on the right side of the brain*. New York: Putnam.

DRAWING ON THE RIGHT SIDE OF THE BRAIN

Farrow, T. F. D., Zheng, Y., Wilkinson, I. D., Spence, S. A., Deakin, J. F. W., Tarrler, N. et al. (2001). Investigating the functional anatomy of empathy and forgiveness. *NeuroReport*, *12*, 2433-2438.

Ferber, S., Mraz, R., Baker, N., & Graham, S. J. (2007). Shared and differential neural substrates of copying versus drawing: a functional magnetic resonance imaging study. *NeuroReport*, *18*, 1089-1093.

Fletcher, P. C., Frith, C. D., Baker, S.C, Shallice, T., Frackowiak, R. S. J. & Dolan, R. (1995). The mind's eye - precuneus activation in memory-related imagery. *NeuroImage*, *2* (3), 195-200.

Gainotti, G. (1985). Constructional apraxia. In J.A.M.Frederiks (Ed.), *Clinical Neuropsychology: Handbook of Clinical Neurology* (pp. 491-506). Amsterdam: Elsevier.

Gaser, C. & Schlaug, G. (2003). Brain structures differ between musicians and non-musicians. *Journal of Neuroscience*, *23*, 9240-9245.

Gilaie-Dotan, S., Harel, A., Bentin, S., Kanai, R., & Rees, G. (2012). Neuroanatomical correlates of visual car expertise. *Neuroimage*, *62*, 147-153.

Grafton, S. T., Mazziotta, J. C., Presty, S., Friston, K. J., Frackowiak, R. S., & Phelps, M. E. (1992). Functional anatomy of human procedural learning determined with regional cerebral blood flow and PET. *Journal of Neuroscience*, *12*, 2542-2548.

DRAWING ON THE RIGHT SIDE OF THE BRAIN

- Hayasaka, S., Phan, K. L., Liberzon, I., Worsley, K. J., & Nichols, T. E. (2004). Nonstationary cluster-size inference with random field and permutation methods. *Neuroimage*, *22*, 676-687.
- Johnson, S. C., Baxter, L. C., Wilder, L. S., Pipe, J. G., Heiserman, J. E., & Prigatano, G. P. (2002). Neural correlates of self-reflection. *Brain*, *125*, 1808-1814.
- Jung, R. E., Segall, J. M., Bockholt, J., Flores, R. A., Smith, S. M., Chavez, R. S. et al. (2010). Neuroanatomy of creativity. *Human Brain Mapping*, *31*, 398-409.
- Koenke, S., Lutz, K., Wustenberg, T., & Jäncke, L. (2004). Long-term training affects cerebellar processing in skilled keyboard players. *NeuroReport*, *15*, 1279-1282.
- Kozbelt, A. (2001). Artists as experts in visual cognition. *Visual Cognition*, *8*, 705-723.
- Kozbelt, A. & Seeley, W. P. (2007). Integrating art historical, psychological and neuroscientific explanations of artists' advantage in drawing and perception. *Psychology of Aesthetics, Creativity and the Arts*, *1*, 80-90.
- Lee, K.-M., Chang, K.-H., & Roh, J.-K. (1999). Subregions within the supplementary motor area activated at different stages of movement preparation and execution. *Neuroimage*, *9*, 117-123.
- Maddock, R. J., Garrett, A. S., & Buonocore, M. H. (2003). Posterior cingulate cortex activation by emotional words: fMRI evidence from a valence decision task. *Human Brain Mapping*, *18*, 30-41.

DRAWING ON THE RIGHT SIDE OF THE BRAIN

Maguire, E. A., Gadian, D. G., Johnsrude, I. S., Good, C. D., Ashburner, J., Frackowiak, R. S. J. et al. (2000). Navigation-related structural changes in the hippocampi of taxi drivers. *Proceedings of the National Academy of Sciences of the United States of America*, *97*, 4398-4403.

Makuuchi, M., Kaminaga, T., & Sugishita, M. (2003). Both parietal lobes are involved in drawing: a functional MRI study and implications for constructional apraxia. *Cognitive Brain Research*, *16*, 338-347.

Manni, E. & Petrosini, L. (2004) A century of cerebellar somatotopy: a debate representation. *Nature Reviews Neuroscience.*, *5*, 241-249.

Mayka, M. A., Corcos, D. M., Leurgans, S. E., & Vaillancourt, D. E. (2006). Three-dimensional locations and boundaries of motor and premotor cortices as defined by functional brain imaging: a meta-analysis. *Neuroimage*, *31*, 1453-1474.

Miall, C. R., Gowen, E., & Tchalenko, J. (2009). Drawing cartoon faces - a functional imaging study of the cognitive neuroscience of drawing. *Cortex*, *45*, 394-406.

Molinari, M., Leggio, M. G., Solida, A., Ciorra, R., Misciagna, S., Silveri, M. C. et al. (1997). Cerebellum and procedural learning: evidence from focal cerebellar lesions. *Brain*, *120*, 1753-1762.

Murphy, F. C., Nimmo-Smith, I., & Lawrence, A. D. (2003). Functional neuroanatomy of emotions: a meta-analysis. *Cognitive, Affective and Behavioural Neuroscience*, *3*, 207-233.

Nachev, P., Kennard, C., & Husain, M. (2008). Functional role of the supplementary and pre-supplementary motor areas. *Nature Neuroscience*, 9, 856-869.

Northoff, G., Heinzel, A., de Greck, M., Bermpohl, F., Dobrowolny, H., & Panksepp, J. (2006). Self-referential processing in our brain - a meta-analysis of imaging studies on the self. *Neuroimage*, 31, 440-457.

O'Connor, N. & Hermelin, B. (1987b). Visual and memory motor programmes: their use by idiot-savant artists and controls. *British Journal of Psychology*, 78, 307-323.

Passingham, R. E. (1996). Functional specialization of the supplementary motor area in monkeys and humans. In H.O.Luders (Ed.), *Advances in Neurology: Supplementary Sensorimotor Area* (pp. 105-116). Philadelphia, PA: Lippincott-Raven.

Schlaug, G. (2001). The brain of musicians: a model for functional and structural plasticity. *Annals of the New York Academy of Sciences*, 930, 281-299.

Schlaug, G., Jäncke, L., Huang, Y., & Steinmetz, H. (1995). In-vivo evidence of structural brain asymmetry in musicians. *Science*, 267, 699-701.

Schlegel, A., Fogelson, S., Li, X., Lu, Z., Alexander, P., Meng, M. et al. (2012). Visual art training in young adults changes neural circuitry in visual and motor areas. *Journal of Vision*, 12, 1129.

Seeley, W. W., Matthews, B. R., Crawford, R. K., Gorno-Tempini, M. L., Foti, D., Mackenzie, I. R. et al. (2008). Unravelling Boléro: progressive aphasia, transmodal creativity and the right posterior neocortex. *Brain*, 131, 39-49.

DRAWING ON THE RIGHT SIDE OF THE BRAIN

Solso, R. L. (2000). The cognitive neuroscience of art: a preliminary fMRI observation. *Journal of Consciousness Studies*, 7, 75-86.

Solso, R. L. (2001). Brain activities in a skilled versus a novice artist: an fMRI study. *Leonardo*, 34, 31-34.

Takeuchi H., Taki Y., Sassa Y., Hashizume H., Sekiguchi A., Fukushima A., et al. (2010). Regional gray matter volume of dopaminergic system associate with creativity: evidence from voxel-based morphometry. *Neuroimage* 51, 578–585

Torriero, S., Oliveri, M., Koch, G., Lo Gerfo, E., Salermo, S., Petrosini, L. et al. (2007). Cortical networks of procedural learning: evidence from cerebellar damage. *Neuropsychologia*, 45, 1208-1214.

van der Meer, L., Costafreda, S., Aleman, A., & David, A. S. (2010). Self-reflection and the brain: a theoretical review and meta-analysis of neuroimaging studies with implications for schizophrenia. *Neuroscience and Biobehavioural Reviews*, 34, 935-946.

Völlm, B. A., Taylor, A. N., Richardson, P., Corcoran, R., Stirling, J., McKie, S. et al. (2006). Neuronal correlates of theory of mind and empathy: a functional magnetic resonance imaging study in a nonverbal task. *Neuroimage*, 29, 90-98.

Wiesendanger, M. (1993). The riddle of supplementary motor area function. In N. Mano, I. Hamada, & M. R. DeLong (Eds.), *Role of the Cerebellum and Basal Ganglia in Voluntary Movements* (pp. 253-266). New York, NY: Elsevier.

DRAWING ON THE RIGHT SIDE OF THE BRAIN

Woollett, K., & Maguire, E. A. (2011). Acquiring "the Knowledge" of London's layout drives structural brain changes. *Current Biology*, *21*, 2109-2114.

Zatorre, R. J. (2003). Music and the brain. *Annals of the New York Academy of Sciences*, *999*, 4-14.